

## Protective Effect of Copper (I)-Nicotinate Complex on DAB-Induced Hepatocellular Carcinoma in Rats

Mohamed A. Abdel-Mohsen <sup>1\*</sup>, Amany I. Youssef <sup>1</sup>, Tarek S. El Sewedy <sup>1</sup>, Morsy A. Abou-Youssef <sup>2</sup>, Hala K. Maghraby <sup>3</sup>, Ashgan I. El-Sarha <sup>3</sup>, Mohammad H. Abd-Elrazak <sup>4</sup>, Ahmed A. El-Gamal <sup>4</sup>, Amr G. Dardeer <sup>4</sup>

<sup>1</sup>Department of Applied Medical Chemistry, Medical Research Institute, Alexandria University

<sup>2</sup>Department of Chemistry, Faculty of Science, Alexandria University

<sup>3</sup>Department of Pathology, Medical Research Institute, Alexandria University

<sup>4</sup>Chemist, Medical Technology Center, Medical Research Institute, Alexandria University

**Received:** 17 April 2017

**Accepted:** 1 June 2017

**Available online:** 10 June 2017

### Keywords

- Copper (I)-Nicotinate Complex
- Hepatocellular carcinoma
- Angiogenesis
- Apoptosis
- Anticancer

### Abstract

The aim of the present work was to evaluate the effect of copper (I)-nicotinate complex (CNC) on experimentally 4-Dimethylaminoazobenzene (DAB)-induced hepatocellular carcinoma (HCC) in male rats. In addition to the histopathological examination we measured hepatic glutathione content, malondialdehyde, nitric oxide levels, lamin B1 m-RNA, caspase-3 activity and serum interleukin-12 level after 2, 4, 6, 8 months from commencement of the experiment. **Results:** histopathological examination showed HCC development after 4 months of DAB administration. The hepatic glutathione content, lamin B1 m-RNA and nitric oxide levels were significantly elevated, while malondialdehyde, interleukin-12 levels and caspase-3 activity were significantly decreased with the progression and development of the HCC. On the other hand, administration of CNC one month before DAB delayed the development of neoplastic growth to the 8<sup>th</sup> month. Interestingly, when CNC was administered one month after DAB, it successfully prevented HCC development throughout the whole experiment as confirmed by histopathological data and explained by biochemical markers, as glutathione, lamin B-1 and nitric oxide were significantly declined but malondialdehyde, interleukin-12 and caspase-3 activity were significantly elevated compared to that in corresponding control group. **Conclusion:** CNC was able to delay or prevent HCC development in rats fed with the potent liver carcinogen DAB. Our data shows that CNC exerts its anti-tumour effects through modulating oxidative stress status as well as the machinery of apoptosis and angiogenesis. Therefore, CNC may be used as a potential protective anticancer agent.

## Introduction

Hepatocellular carcinoma (HCC) is the third deadliest and fifth most common malignancy worldwide (1). In Egypt liver cancer represents about 33.6% of all cancers in males and 13.5% in females (2). Chemically-induced hepatocarcinogenesis in experimental models allows us to observe the similarity between the development of cancer in laboratory animals and in human; several chemical agents have been used in the induction of HCC in animals including N-nitrosodimethylamine (DMN) and 4-Dimethylaminoazobenzene (DAB) (3). The carcinogenic action of DAB is influenced by diet, the addition of dried milk or yeast to a diet of brown rice and carrots with DAB delayed and reduced the incidence of tumors while addition of pyridoxine, vitamin B12 or biotin increased its carcinogenic action (4).

Decreased apoptosis and increased angiogenesis are considered to be two major hallmarks of cancer (5). Biomarkers or modulators of apoptosis, angiogenesis and oxidative stress status have been traditionally used to study and monitor the progression and response of cancer cells to any potential treatment (6).

The challenge of discovering new drugs that are able to induce apoptosis and suppress angiogenesis is of a great interest in cancer treatment (7). Metal coordination complexes have been clinically used in as anti-cancer agents focusing on the use of ions such as copper (Cu) (8). The first evidence that copper complexes may exert antitumor efficacy is traced back to the early 1960s (9). Later, it has been reported that copper (I)-nicotinate complex

(CNC) may improve the prognosis of HCC patients when combined with 5-fluorouracil (10). Some studies have also investigated the potential role of CNC to modulate lipid peroxidation processes and products that have a profound impact on the development of neoplastic diseases (11, 12). The most recent CNC study was conducted on HCC1806 human breast cancer cell line has suggested an anti-tumour and an anti-autophagy role for CNC (13). Nevertheless, a protective anti-tumour action of CNC and the potential molecular mechanisms involved were not previously investigated in details.

The aim of this work was to evaluate the potential protective anticancer effect of CNC as well as the mechanisms involved in this action on experimentally DAB-induced HCC in rats. This was performed by measuring lamin B1 m-RNA expression level as a biomarker of HCC progression (14), hepatic glutathione (GSH) content as an anti-oxidant molecule (15) and hepatic malondialdehyde level (MDA) as a biomarker of lipid peroxidation process (16). On the other hand, Caspase-3 activity, hepatic Nitric Oxide (NO) and interleukin-12 (IL-12) levels were also measured as a biomarkers and modulators of apoptosis and angiogenesis (17-20). Histopathological examination of hepatic tissue was performed to monitor the progression of liver tumour and to correlate biochemical data with histopathological findings.

## Materials and Methods

### I. Chemicals and reagents

The DAB used for HCC induction is a product of "Biobasic, Canada". Nicotinic acid was purchased

from “Loba Chemic, India”. Caspase-3 colorimetric assay kit (cat # K106-200) was purchased from “Biovision Co., USA”, IL-12 kit purchased from “Cusabio Biotech, China. QIAamp RNA blood mini kit was purchased from Qiagen, PCR and cDNA reagents were purchased from MBI Fermentas, Lithuania, all other chemicals and reagents were analytical grade and purchased from Sigma, USA. The CNC was prepared according to a method proposed by Goher et al. (21).

## II. Animals and experimental design

This study was carried out on two hundred, 2 months old albino male rats with average weight of 70-90 g. All animal procedures were conducted in accordance with the standard guidelines for the care and use of experimental animals by the medical research ethics committee, Medical Research Institute, Alexandria University, Egypt.

Animals were divided into 5 groups and 40 rats in each group were fed on:

Group (A): Normal balanced diet as control animals.

Group (B): Normal balanced diet containing 0.06 g DAB / 100 g diet daily (22) till the appearance of the tumor as revealed by histopathological examination.

Group (C): Oral CNC daily in a dose of 1 mg/kg body weight for 8 months (23).

Group (D): CNC dose of 1 mg/kg body weight for 8 months starting one month before DAB administration.

Group (E): CNC dose of 1 mg/kg body weight for 8 months starting one month after DAB administration.

Ten rats from control group were randomly chosen and sacrificed representing starting time for the experiment while seven rats were randomly chosen from each group at the time intervals of 2<sup>nd</sup>, 4<sup>th</sup>, 6<sup>th</sup> and 8<sup>th</sup> month post DAB administration for histopathological as well as biochemical analysis.

## III. Biochemical analysis

Each rat liver was removed, washed with saline and divided into 2 portions; the first portion was preserved in 10 % formalin for histopathological analysis. The second portion was used for determination of hepatic total nitrite as a marker for (NO) production using Griess reaction (24), Caspase-3 activity using a colorimetric commercial kit following the manufacturer’s instructions and the results were expressed by the fold-change in caspase-3 activity between samples and control. GSH content was measured as described by Olson et al. (25), MDA level as described by Takikawa et al. (26) and Serum IL-12 as described by Lauwerys et al. (27).

For the determination of Lamin B1 mRNA expression level, total RNA was extracted from whole blood samples using the QIAamp RNA blood mini kit. cDNA was prepared using the RevertAid™ first strand cDNA synthesis kit following the manufacturer’s instructions. Finally, PCR with a total of 35 cycles was performed using the DreamTaq™ Green PCR Master Mix. The sequence of Lamin B1 (28) and GAPDH (29) primers used are shown in the following table:

Primer	Nucleotide sequence
Lamin B1	5' TCA GGA GA GGA GGT TGCTC 3'
	<b>5' TCACATAATGGCACAGCTTTTAT 3'</b>
GAPDH	5' CAAGGTCATCCATGA CAAC TTTG 3'
	<b>5' GTCCACCACCCTGTTGCTGTAG 3'</b>

Reverse primers are shown in bold

#### IV. Histopathological Examination

A tissue sample from rat liver was fixed in 10% formaline-saline and embedded in paraffin blocks. A representative 4  $\mu$ m thin section was then stained using hematoxylin and eosin (H&E) stain (30) and photomicrographs were taken at 400 x.

#### V. Statistical methods

Data are expressed as mean  $\pm$  SE. results were statistically analyzed using statistical package for social science (SPSS) version 11.5 for windows. ANOVA test was for multiple comparisons of the mean levels of different biochemical markers in different groups. The minimum level of statistical significance was set at  $P \leq 0.05$ .

#### Results:

##### I. Histopathological examination:

Histopathological examination of rat liver tissue for control group (A) and group (C) showed preservation of hepatic architecture and normal hepatocytes throughout the whole experiment (Fig. 1A) with mild lymphocytic infiltration observed in group (C) after 8 months of CNC treatment (Fig. 1B). DAB-induced group (B) showed a loss of hepatic architecture with well differentiated cholangiocarcinoma and nodules of HCC with atypical large hepatic cells and large nucleoli starting after 4 months of DAB induction (Fig. 1C).

CNC treated group (D) showed a preservation of hepatic architecture with mild lymphocytic infiltration after 2 months, coagulative necrosis of poorly stained mummified hepatocytes after 4 months (Fig. 2A) and a mild fibrosis and degeneration of hepatocytes after 6 months. Loss

of definition of liver architecture and neoplastic growth was observed after 8 months (Fig. 2B). Most interestingly, microscopic examination of rat liver of group (E) showed a preserved hepatic architecture throughout the whole 8 months duration of the experiment with no necrosis or any neoplastic cells observed (Fig. 2C).

#### II. Biochemical analysis:

##### 1. Total hepatic nitrite:

In HCC induced group (B) rats, significant increase in hepatic nitrite at different time intervals was detected compared to all other groups. Hepatic nitrite of group (E) was significantly lower than the corresponding values of group (D) at all time intervals of the experiment (Table 1).

##### 2. Serum Interlukin-12:

For group (B), the concentration of serum IL-12 decreased significantly at 4, 6, 8 months compared to all other groups. Serum IL-12 for group (E) was significantly higher than the corresponding levels of group (D) through the different intervals of the experiment (Table 2).

##### 3. Hepatic caspase-3 activity:

The activity of hepatic caspase-3 for group (B) significantly decreased at 2, 4, 6, 8 months compared to all other groups. There was a significant increase in the activity of caspase-3 for group (E) compared to (D) after 4, 6, 8 months which was the highest progressive increase in caspase-3 activity compared to all other groups (Table 3).

**Table 1.** Total hepatic nitrite content (nmol/mg protein)

Group (n=7)	Interval in months			
	2	4	6	8
A	14.9±0.25	16±0.42	15.4±0.51	16.4±0.28
B	20.7±0.35 <sup>⊙</sup>	43±0.61 <sup>⊙</sup>	62±0.67 <sup>⊙</sup>	100.6±1.42 <sup>⊙</sup>
C	12.7±0.38 <sup>⊙, I</sup>	13.4±0.19 <sup>⊙, I</sup>	12.5±0.28 <sup>⊙, I</sup>	13.8±0.32 <sup>⊙, I</sup>
D	14.3±0.5 <sup>I, N</sup>	28.4±0.36 <sup>⊙, I, N</sup>	41±0.68 <sup>⊙, I, N</sup>	69.7±0.47 <sup>⊙, I, N</sup>
E	13.4±0.3 <sup>⊙, I</sup>	22±0.46 <sup>⊙, I, N, I</sup>	21±0.3 <sup>⊙, I, N, I</sup>	23±0.29 <sup>⊙, I, N, I</sup>

Statistically significant differences between: <sup>⊙</sup> control group (A) & groups (B, C, D & E), **I**: group (B) & groups (C, D & E), **N**: group (C) & groups (D & E) and **T**: group (D) & (E) ( $p \leq 0.05$  was considered significant.). Data are presented as mean  $\pm$  S.E

**Table 2.** Serum IL-12 level (pg/ ml)

Group (n=7)	Interval in months			
	2	4	6	8
A	42±0.96	43±1.03	33±0.87	30±0.59
B	90±2 <sup>⊙</sup>	27±1 <sup>⊙</sup>	19±0.85 <sup>⊙</sup>	9.5±0.58 <sup>⊙</sup>
C	109±1 <sup>⊙, I</sup>	83±1 <sup>⊙, I</sup>	36±1 <sup>⊙, I</sup>	35.4±1 <sup>⊙, I</sup>
D	64±.75 <sup>⊙, I, N</sup>	31±0.9 <sup>⊙, I, N</sup>	17±0.68 <sup>⊙, N</sup>	12±0.71 <sup>⊙, I, N</sup>
E	86±1 <sup>⊙, I, N, T</sup>	52±1.28 <sup>⊙, I, N, T</sup>	25±1 <sup>⊙, I, N, T</sup>	17.3±0.88 <sup>⊙, I, N, T</sup>

Statistically significant differences between: <sup>⊙</sup> control group (A) & groups (B, C, D & E), **I**: group (B) & groups (C, D & E), **N**: group (C) & groups (D & E) and **T**: group (D) & (E) ( $p \leq 0.05$  was considered significant.). Data are presented as mean  $\pm$  S.E

**Table 3.** Hepatic caspase-3 activity (fold-change)

Group (n=7)	Interval in months			
	2	4	6	8
A	1.55±0.05	1.33±0.001	1.21±0.002	1.17±0.02
B	0.86±0.001 <sup>⊙</sup>	0.71±0.001 <sup>⊙</sup>	0.53±0.002 <sup>⊙</sup>	0.44±0.002 <sup>⊙</sup>
C	1.27±0.002 <sup>⊙, I</sup>	1.79±0.001 <sup>⊙, I</sup>	1.27±0.003 <sup>⊙, I</sup>	1.23±0.03 <sup>I</sup>
D	0.69±0.003 <sup>⊙, I, N</sup>	0.93±0.001 <sup>⊙, I, N</sup>	1.09±0.01 <sup>⊙, I, N</sup>	1.07±0.03 <sup>⊙, I, N</sup>
E	0.65±0.002 <sup>⊙, I, N, I</sup>	1.58±0.019 <sup>⊙, I, N, I</sup>	1.87±0.02 <sup>⊙, I, N, I</sup>	2.15±0.015 <sup>⊙, I, N, I</sup>

Statistically significant differences between: <sup>⊙</sup> control group (A) & groups (B, C, D & E), **I**: group (B) & groups (C, D & E), **N**: group (C) & groups (D & E) and **T**: group (D) & (E) ( $p \leq 0.05$  was considered significant.). Data are presented as mean  $\pm$  S.E

**Table 4.** Hepatic glutathione content (mg/ g liver tissue)

Group (n=7)	Interval in months			
	2	4	6	8
A	2.75 $\pm$ 0.03	2.79 $\pm$ 0.02	2.70 $\pm$ 0.03	2.72 $\pm$ 0.03
B	2.57 $\pm$ 0.02 <sup>⊙</sup>	5.63 $\pm$ 0.08 <sup>⊙</sup>	7.93 $\pm$ 0.12 <sup>⊙</sup>	9.25 $\pm$ 0.02 <sup>⊙</sup>
C	2.69 $\pm$ 0.02 <sup>I</sup>	2.16 $\pm$ 0.03 <sup>⊙, I</sup>	2.12 $\pm$ 0.02 <sup>⊙, I</sup>	2.08 $\pm$ 0.08 <sup>⊙, I</sup>
D	3.40 $\pm$ 0.12 <sup>⊙, I, N</sup>	5.50 $\pm$ 0.05 <sup>⊙, N</sup>	5.37 $\pm$ 0.12 <sup>⊙, I, N</sup>	7.93 $\pm$ 0.09 <sup>⊙, I, N</sup>
E	2.83 $\pm$ 0.04 <sup>⊙, I, T</sup>	4.35 $\pm$ 0.03 <sup>⊙, I, N, T</sup>	3.22 $\pm$ 0.02 <sup>⊙, I, N, T</sup>	1.65 $\pm$ 0.02 <sup>⊙, I, N, T</sup>

Statistically significant differences between: <sup>⊙</sup> control group (A) & groups (B, C, D & E), **I**: group (B) & groups (C, D & E), **N**: group (C) & groups (D & E) and **T**: group (D) & (E) ( $p \leq 0.05$  was considered significant.). Data are presented as mean  $\pm$  S.E

#### 4. Hepatic glutathione content:

The hepatic GSH content for group (B) was significantly higher compared all other groups. Group E showed significant lower values of hepatic GSH at all different time intervals of the experiment compared to corresponding values of group (D) (Table 4).

#### 5. Hepatic Malondialdehyde level:

Group (B) showed significant gradual decrease in hepatic MDA level along the different time intervals compared to all other groups. Group E showed significant increase in hepatic MDA compared to group (D) throughout the whole duration of the experiment (Table 5).

#### F. Expression Lamin B1-mRNA:

After 2 months of the experiment, the expression of lamin B1 was almost equal in all studied groups. By the eighth month, lamin B1 expression was prominently high in group (B) compared to all other groups while it was almost undetected in group (E) (Fig. 3).

#### Discussion:

Increased CNC consumption is associated with prevention of gastric congestion, anti-ulcer and anti-inflammatory effects (23). Our histopathological data presented in this work demonstrated that CNC treatment has retarded the progression of hepatocarcinogenesis when administrated before DAB induction (group D) but the maximum anticancer protective effect shown by the lack of any malignant growth was observed in rats receiving CNC after DAB induction (Group E). The minimal CNC-induced inflammation which

was observed in the histopathological investigation of CNC group (C) may explain the late progressive liver cancer appeared in group (D) that could be attributed to Cu accumulation.

Our biochemical data clearly demonstrates a pro-apoptotic and anti-angiogenic effect of CNC treatment through the modulation of the Caspase-3 activity, NO and IL-12 levels.

Our data shows a pro-apoptotic effect of CNC reflected by the significant increase in caspase-3 activity in CNC treated rats, an effect that may be modulated through a p53 dependant pathway and diminishing the anti-apoptotic proteins such as Bcl-2 and XIAP (17, 31).

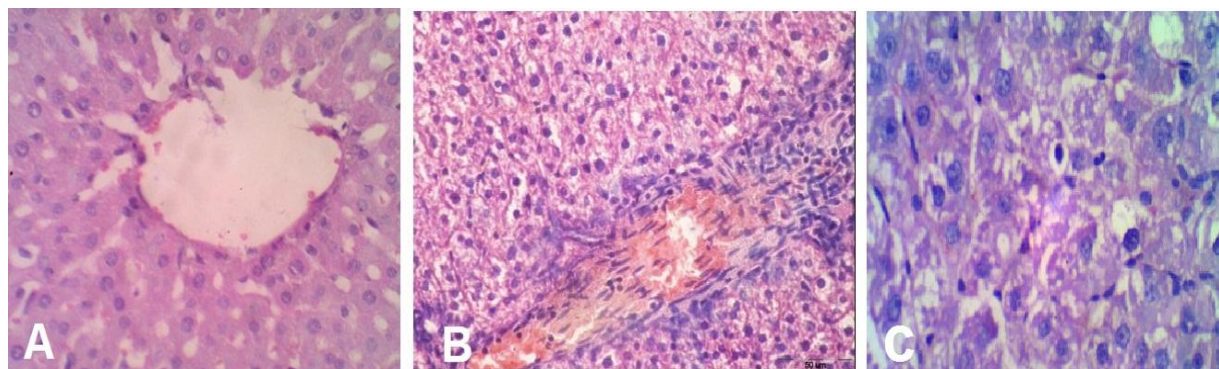
Our data also reveals that CNC treatment significantly reduced the levels of hepatic nitric oxide which is reported to act as anti-apoptotic modulator due to the inactivation of caspase 1, 3 and 8 (18) and as a pro-angiogenic mediator sustaining rapid tumor growth (19). The anti-angiogenic role for CNC was also confirmed by our data showing a significant increase in interleukin-12 after CNC treatment, Interleukin-12 is a well known anti-angiogenic biomarker of angiogenesis (20, 32).

Glutathione participates in many key cancer-related processes, including antioxidant defense and cell proliferation (33). Elevated GSH levels are observed in various types of tumors and this makes the neoplastic tissues more resistant to chemotherapy (15). In agreement with these findings, our data showed that GSH levels were significantly higher in DAB induced HCC rats group (B) compared to CNC treated groups.

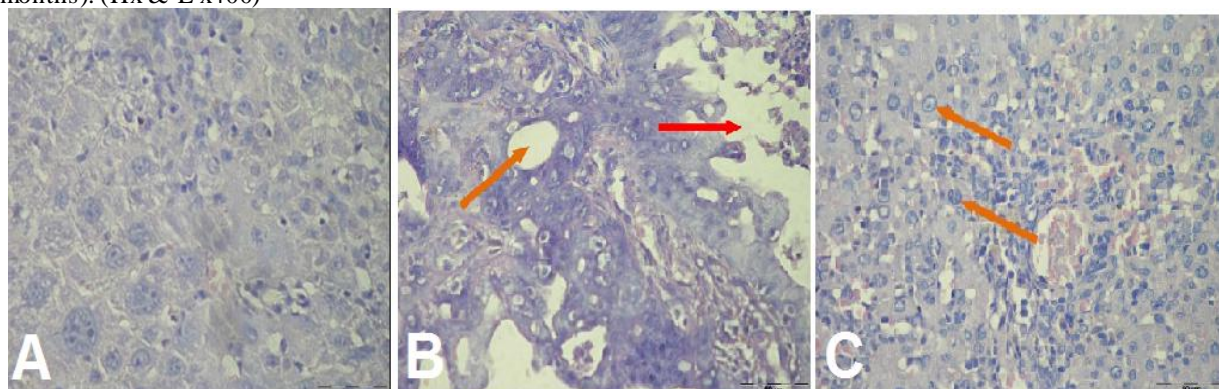
**Table 5.** Hepatic MDA level ( $\mu\text{g/g}$  liver tissue)

Group (n=7)	Interval in months			
	2	4	6	8
A	70.2 $\pm$ 4.5	80.5 $\pm$ 4.2	80.2 $\pm$ 4.2	80.1 $\pm$ 4.1
B	100.1 $\pm$ 4.4 <sup>⊙</sup>	30.5 $\pm$ 2.2 <sup>⊙</sup>	20.5 $\pm$ 4.2 <sup>⊙</sup>	10.5 $\pm$ 0.2 <sup>⊙</sup>
C	80.2 $\pm$ 4.0 <sup>I</sup>	100.5 $\pm$ 4.2 <sup>⊙,I</sup>	90.5 $\pm$ 4.2 <sup>I</sup>	90.5 $\pm$ 4.2 <sup>I</sup>
D	40.2 $\pm$ 4.2 <sup>⊙,I,N</sup>	30.8 $\pm$ 2.1 <sup>⊙,N</sup>	20.2 $\pm$ 4.2 <sup>⊙,N</sup>	10.2 $\pm$ 0.2 <sup>⊙,N</sup>
E	70.5 $\pm$ 2.1 <sup>I,N,T</sup>	70.5 $\pm$ 4.2 <sup>I,N,T</sup>	70.1 $\pm$ 2.1 <sup>⊙,I,N,T</sup>	110.8 $\pm$ 4.2 <sup>⊙,I,N,T</sup>

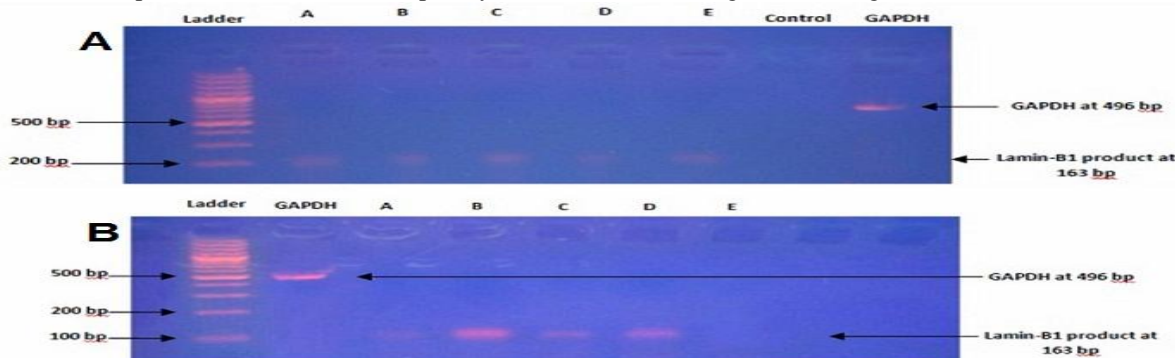
Statistically significant differences between: <sup>⊙</sup> control group (A) & groups (B, C, D & E), <sup>I</sup>: group (B) & groups (C, D & E), <sup>N</sup>: group (C) & groups (D & E) and <sup>T</sup>: group (D) & (E) ( $p \leq 0.05$  was considered significant.). Data are presented as mean  $\pm$  S.E



**Figure 1.** Microscopic examination of rat liver showing **A:** Control group (A) normal liver parenchyma, **B:** CNC-treated group (C) hepatocytes with lymphocytic infiltration (8 months), **C:** DAB-induced group (B) with nodules of HCC (4 months). (Hx & E x400)



**Figure 2.** Microscopic examination of rat liver: **A:** Group (D) at 4 months showing necrosis of poorly stained hepatocytes, **B:** Group (D) at 8 months revealing a neoplastic growth made malignant cuboidal to columnar cells lined dilated cyst (red arrow), ducts and forming cribriform pattern (orange arrow), **C:** Group (E) at 8 months revealing preservation of hepatic architecture, some hepatocytes show nuclear enlargement (orange arrows). (Hx & E x400).



**Figure 3.** PCR Agarose gel electrophoresis showing Lamin-B1 expression: **A:** After 2 months, **B:** After 8 months. The PCR amplification products of lamin B1 and GAPDH control were 163 and 496 bp respectively

Malondialdehyde (MDA) is one of the byproducts of lipid peroxidation and is one of the most frequently used biomarkers of the overall lipid peroxidation (16). It was previously reported that MDA levels detected in HCC tissue were significantly lower than the corresponding non-tumour liver tissue indicating a resistance to lipid peroxidation and increased survival within tumour cells (34). Our data shows a significant progressive increase in MDA levels in CNC treated groups reflecting an increased lipid peroxidation leading to increased cancer cell damage upon CNC treatment.

Lamin B1 is essential for cell survival (35) and it is overexpressed in early and late stage HCC (14). Our data has demonstrated a gradual decrease in hepatic lamin B1 m-RNA in CNC treated groups, becoming nearly undetected by the end of the experiment reflecting an increase rate of cancer cell death due to CNC treatment.

Our biochemical and histopathological data proves that CNC have an effective protective effect against DAB-induced liver carcinogenesis which might be attributed to the CNC as a good supplier of Cu. It has been reported that binding of the DAB to liver proteins is of a vital importance to its carcinogenic process and that Cu acts through competitive binding manner with the DAB for the available sites on the protein molecules (36). DAB detoxifying pathways are assumed to be through azoreductase and ring hydroxylase, which lead to inactive derivatives eliminated in urine (37). It has been reported that the Cu administration enhances the activity of azoreductase and ring hydroxylase enzymes (38). Therefore, the possible anticarcinogenic activity of CNC could be attributed either to diminish of DAB binding to

liver proteins or enhanced activity of its detoxification enzymes.

Cu is also one of the key components of antioxidant mechanisms. CNC provides Cu to hepatocytes that accelerate the biosynthesis of SOD (36) which effectively suppress the growth of cancer cells (39). Additionally, it has been reported that CNC has SOD-mimic activity (23). Since redox properties of Cu render it able to eliminate  $O^{\cdot 2}$  and potential scavenger of  $ONOO^{\cdot}$  (40). Therefore, the anticarcinogenic activity of CNC could also be viewed through the enhancement of SOD biosynthesis and/or its SOD-mimic effect.

**Conclusion:** CNC treatment may attenuate or prevent DAB-induced HCC through the induction of apoptosis, DAB detoxification and the inhibition of angiogenesis as well as modulation of oxidative stress and lipid peroxidation processes.

#### References:

1. **Wong, M. C. S. et al.** International incidence and mortality trends of liver cancer: a global profile. *Sci. Rep.* 7, 45846; doi: 10.1038/srep45846, 2017.
2. **Ibrahim AS, Khaleed HM, Mikhail NN, et al:** Cancer incidence in Egypt: results of the national population-based cancer registry program. *J Cancer Epidemiol.* 437-971, 2014.
3. **Ito N, Tsuda H, Hasegawa R, Imaida K.** Comparison of the promoting effects of various agents in induction of preneoplastic lesions in rat liver. *Environ Health Perspect.* 50:131–138, 1983.
4. **Miller EC and Miller JA.** The presence and significance of bound aminoazo dyes in the livers of rats fed p-dimethylaminoazobenzene. *Cancer Res.* 7: 468- 80. 1947.



5. **Hanahan D, Weinberg RA**: The hallmarks of cancer. *Cell* 100 (1):57-70, 2000.
6. **Hamed EA, Zakhary MM, Maximous DW**. Apoptosis, angiogenesis, inflammation, and oxidative stress: basic interactions in patients with early and metastatic breast cancer. *J Cancer Res Clin Oncol*. 138(6):999–1009. 2012.
7. **Yun SM, Lee JH, Jung KH, Lee H, Lee S, Hong S, Hong SS**: Induction of apoptosis and suppression of angiogenesis of hepatocellular carcinoma by HS-159, a novel phosphatidylinositol 3-kinase inhibitor. *Int J Oncol*. 43(1):201- 9. 2013.
8. **Marzano C, Pellei M, Tisato F & Santini C**. Copper complexes as anticancer agents. *Anti-Cancer Agents in Medicinal Chemistry*. 9, 185–211. 2009.
9. **Crim JA, Petering HG**: The antitumor activity of Cu (II) KTS, the copper (II) chelate of 3-ethoxy-2-oxobutyralsdehyde bis(thiosemicarbazone). *Cancer Res*. 27(7):1278-1285, 1967.
10. **El-Saadani M**: A combination therapy with copper nicotinate complex reduces the adverse effects of 5-fluorouracil on patients with hepatocellular carcinoma. *Journal of Experimental Therapeutics & Oncology*. 4(1):19-24. 2004.
11. **El-Saadani M, Esterbauer H, El-Sayed M, Gohar M, Nassar AY, Jurgens G**. In vivo and in vitro effects of copper (I) nicotinic acid Complex on lipid and lipoprotein. *Agent Action Suppl*. 26: 247- 58. 1988.
12. **El-Saadani M, Esterbauer H, El-Sayed M, Gohar M, Nassar AY, Jurgens G**. A copper and copper-nicotinic acid complexes mediated oxidation of high density lipoprotein. *Basic Life Sci*. 49: 381-5. 1989.
13. **Abdel-Mohsen MA, El-Shafey ES, Malak CA, Abou-Yossef MM**. Antitumor Activity of Copper (I)-Nicotinate Complex and Autophagy Modulation in HCC1806 Breast Cancer Cells. *Anticancer Agents Med Chem*. (17). 2017. DOI: 10.2174/1871520617666170327144122
14. **Sun, S., Xu, M.Z., Poon, R.T., Day, P.J. and Luk, J.M.** Circulating lamin B1 (LMNB1) biomarker detects early stages of liver cancer in patients. *J Proteome Res*. 9, 70–78. 2010.
15. **Nicola T, Ricciarelli R, Nitti M, Marengo B, Furfaro AL, Pronzato MA, et al**: Role of glutathione in cancer progression and chemoresistance. *Oxid. Med. Cell. Longev*. 972913-972923, 2013.
16. **Ayala, A., Muñoz, M. F., and Argüelles, S.** Lipid peroxidation: production, metabolism, and signaling mechanisms of malondialdehyde and 4-hydroxy-2-nonenal. *Oxid. Med. Cell. Longev*. 1–31. 2014.
17. **Abu-Qare AW, Abou-Donia MB**: Biomarkers of apoptosis: release of cytochrome c, activation of caspase-3, induction of 8-hydroxy-2'-deoxyguanosine, increased 3-nitrotyrosine, and alteration of p53 gene. *J Toxicol Environ Health B Crit Rev*. 4(3):313-32, 2001.
18. **Choi B. M., Pae H. O., Jang S. I., Kim Y. M. and Chung H. T.** Nitric oxide as a pro-apoptotic as well as anti-apoptotic modulator. *BMB Rep*. 35: 116–126, 2002.
19. **Ridnour LA, et al**. Nitric oxide regulates angiogenesis through a functional switch involving thrombospondin-1. *Proc Natl Acad Sci*. 102:13147–13152. 2005.
20. **Sgadari C, Angiolillo AL, Tosato G**: Inhibition of angiogenesis by interleukin-12 is

- mediated by the interferon-inducible protein 10. *Blood*. 87(9):3877-3882, 1996.
21. **Goher MA, Mak TCW**: Crystal structure of a polymeric 2:1 complex of nicotinic acid with copper (I) chloride. *Inorganica Chimica Acta* 127(1): L13-L16, 1987.
22. **Miller EC, Miller JA, Kline BE, Rusch HP**: Correlation of the level of hepatic riboflavin with the appearance of liver tumors in rats fed aminoazo dyes. *J Exp Med*. 88(1):89-98, 1948.
23. **El-Saadani MA, Nassar AY, Abou el-Ela SH, Metwally TH, Nafady AM**: The protective effect of copper complexes against gastric mucosal ulcer in rats. *Biochem Pharmacol*. 46(6):1011-1018. 1993.
24. **Tsikás D**: Analysis of nitrite and nitrate in biological fluids by assays based on the Griess reaction: appraisal of the Griess reaction in the L-arginine/nitric oxide area of research. *J Chromatogr B Analyt Technol Biomed Life Sci*. 851(1-2):51-70, 2007.
25. **Olson RD, MacDonald JS, vanBoxtel CJ, Boerth RC, Harbison RD, Slonim AE, Freeman RW, Oates JA**: Regulatory role of glutathione and soluble sulfhydryl groups in the toxicity of adriamycin. *J Pharmacol Experimen Therap*. 215(2):450-454, 1980.
26. **Takikawa O, Yoshida R, Kido R, Hayashi OJ**: Pathogenesis of dengue: challenges to molecular biology. *Biol Chem* 261(1): 3648-53, 1988.
27. **Lauwerys BR, Renaud JC, Houssiau FA**: Synergistic proliferation and activation of natural killer cells by interleukin 12 and interleukin 18. *Cytokine* 11(11):822-830, 1999.
28. **Laurent V, Péterfy M, Bergo MO, Young SG, Reue K**: Lamin B1 is required for mouse development and nuclear integrity. *Proc Natl Acad Sci*. 101(28):10428-10433, 2004.
29. **Yao Z, Huang LZ, Yang QL, Liu Y, Xin Zhou**: Correlation analysis between ApoM gene-promoter polymorphisms and coronary heart disease. *Cardiovasc J Afr*. 27(4): 228-237, 2016.
30. **Fischer AH, Jacobson KA, Rose J, Zeller R**: Hematoxylin and eosin staining of tissue and cell sections. *CSH Protoc*. 49-86, 2008.
31. **Rhee J.-S., Yu I.T., Kim B.M., Jeong C.B., Lee K.W., Kim M.J., Lee S.J., Park G.S., Lee J.S.** Copper induces apoptotic cell death through reactive oxygen species-triggered oxidative stress in the intertidal copepod *Tigriopus japonicus*. *Aquat. Toxicol*. 132:182–189. 2013.
32. **Syed MM, Katiyar S, Elmets CA, Katiyar SK**: Interleukin-12 deficiency is permissive for angiogenesis in UV radiation-induced skin tumors. *Cancer Res*. 67(8):3785-3793, 2007.
33. **Harold SE**: Oxidative stress and antioxidants: a link to disease and prevention?. *J Nutr Biochem*. 18(3):168-71. 2007.
34. **Jüngst C, Cheng B, Gehrke R, Schmitz V, Nischalke HD, Ramakers J, Schramel P, Schirmacher P, Sauerbruch T, Caselmann WH**. Oxidative damage is increased in human liver tissue adjacent to hepatocellular carcinoma. *Hepatology*. 39: 1663–1672. 2004.
35. **Harborth, J., Elbashir, S.M., Bechert, K., Tuschl, T. and Weber, K.** Identification of essential genes in cultured mammalian cells using

small interfering RNAs. *J. Cell Sci.* 114, 4557–4565. 2001.

36. **Klotz LO, Kröncke KD, Buchczyk DP, Sies H:** Role of copper, zinc, selenium and tellurium in the cellular defense against oxidative and nitrosative stress. *J Nutr.* 133:1448S–1451S, 2003.

37. **Ricco J, Franco D, Morin J, Decloitre F and Bismuth H.** Modifications of 3'-Methyl-4-dimethylaminoazobenzene Carcinogenesis of Rat Liver and Carcinogen Metabolism by Portacaval Anastomosis. *Cancer Res.* 37: 4500- 5. 1977.

38. **Yamane Y and Sakai K.** Effect of basic cupric acetate on biochemical changes in the liver of the rat fed carcinogenic aminoazo dye. III. Effect of copper compared with some other metals, phenobarbital and 3-methylcholanthrene on the metabolism of 4-dimethylaminoazobenzene. *Chem Pharm Bull (Tokyo);* 22: 1126- 32. 1974.

39. **Caraglia M, Giuberti G, Marra M, Addeo R, Montella L, Murolo M, Sperlongano P, Vincenzi B, Naviglio S, Prete SD, et al.** Oxidative stress and ERK1/2 phosphorylation as predictors of outcome in hepatocellular carcinoma patients treated with sorafenib plus octreotide LAR. *Cell Death Dis.* 2011;2:e150. doi: 10.1038/cddis.2011.34

40. **Ferrer-Sueta G, Vitturi D, Batinic-Haberle I, Fridovich I, Goldstein S, Czapski G, Radi R.** Reactions of manganese porphyrins with peroxyxynitrite and carbonate radical anion. *J Biol Chem.* 278:27432–27438. 2003.